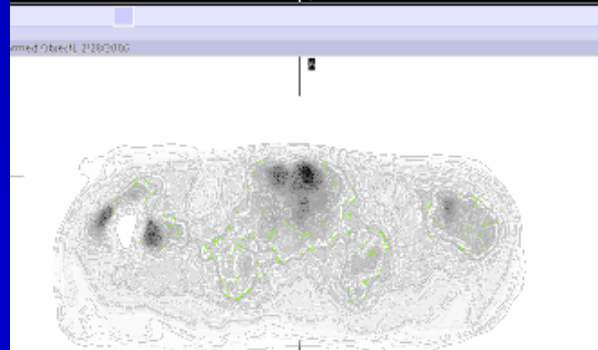
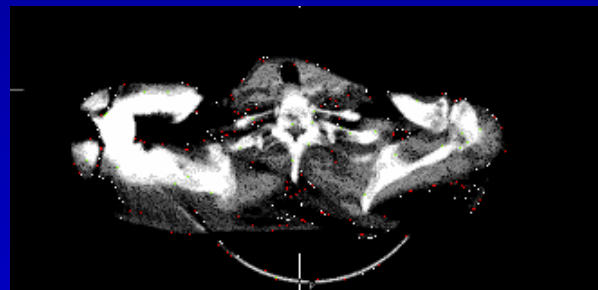
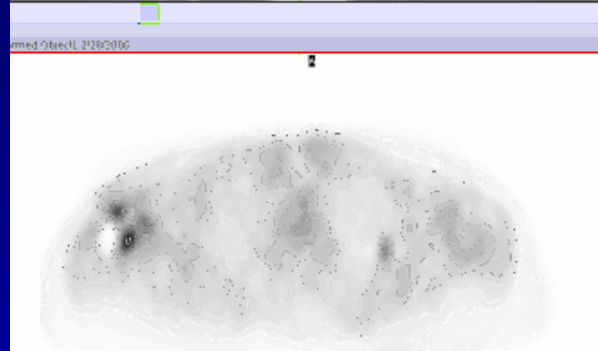
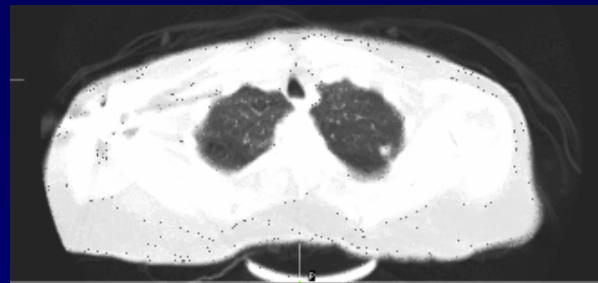
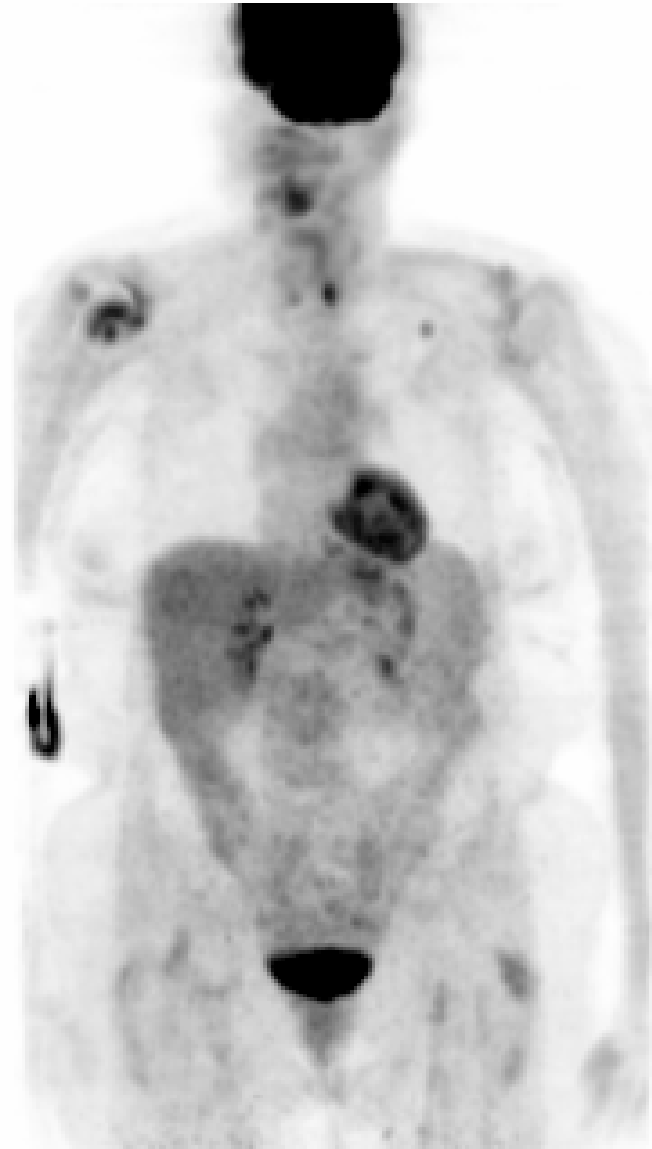

1

Case 102

The images shows focal hypermetabolism in the inferior pole of the left lobe of thyroid, an incidental finding, but suspicious for neoplastic involvement and should be evaluated further. Also, focal hypermetabolism is seen in the left upper lobe lung nodule. Although the SUV is only 1.8, it is still suspicious for neoplastic involvement as visually, it is more active than the surrounding mediastinal blood pool activity. There is no definite evidence of metastatic disease. Non specific inflammatory activity is seen around the right shoulder prosthesis. Injection artifact is seen in the right forearm.