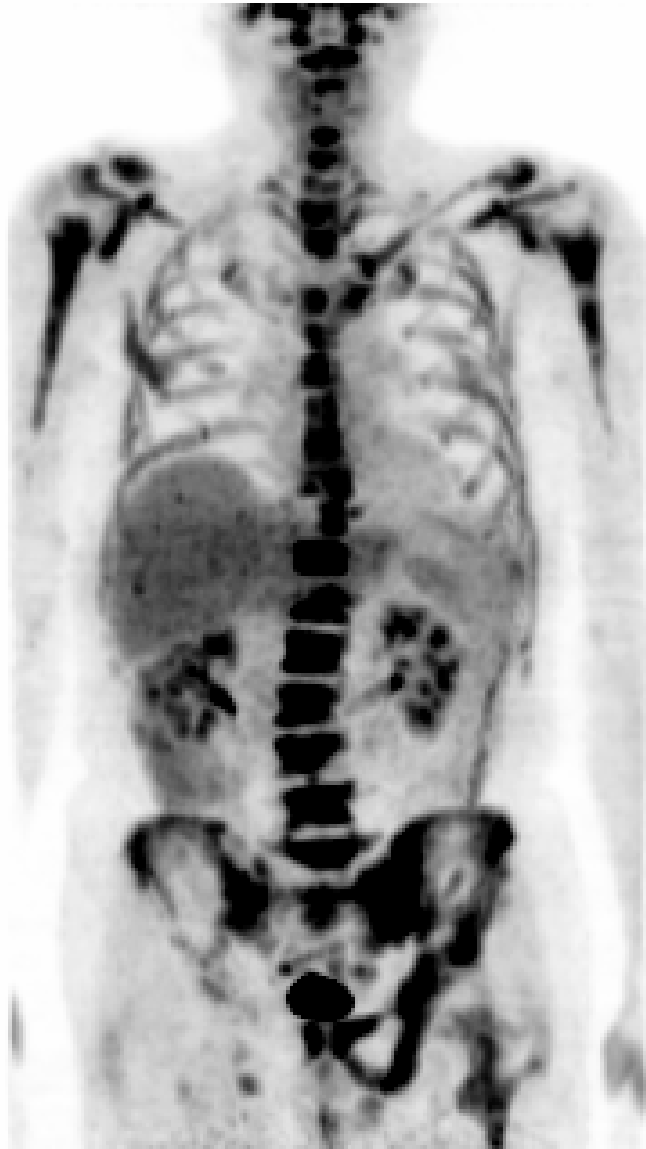
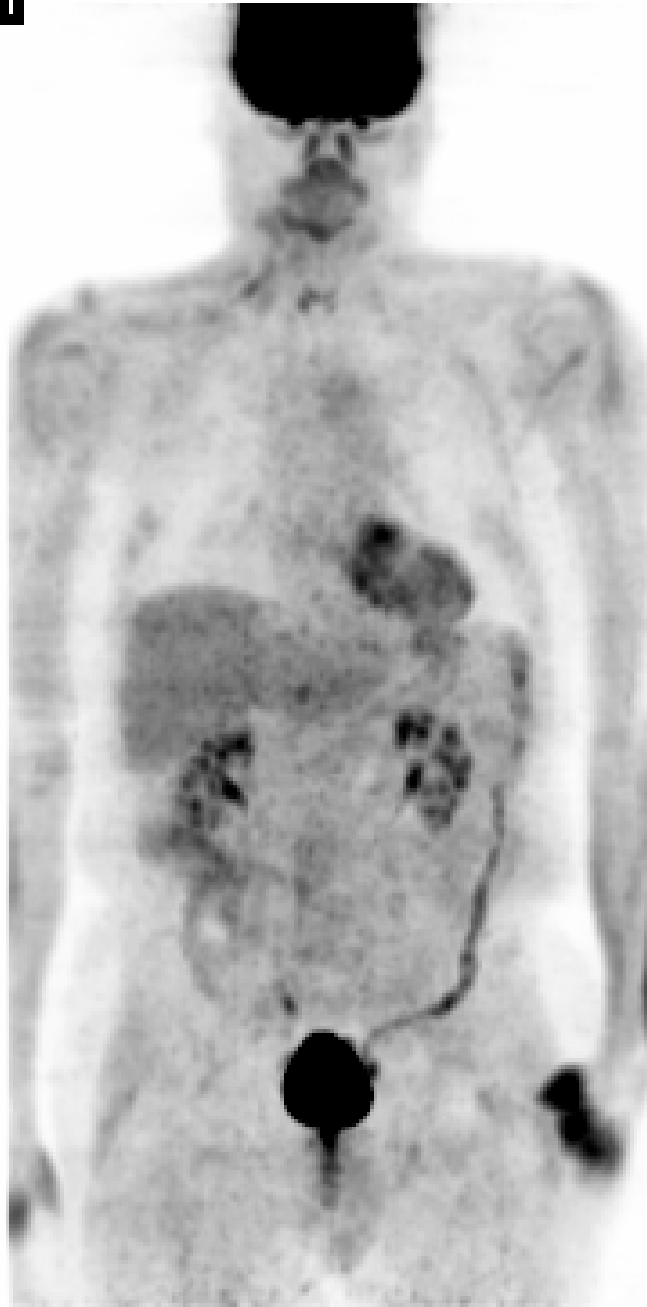


**1****1**

### Case 103

The prechemotherapy image (left) shows intense hypermetabolism in the bones, in the distribution of active marrow, consistent with known diagnosis of lymphoma. No definite evidence of any soft tissue lesions. The post therapy image (right) shows resolution of the hypermetabolic foci and no definite evidence of active neoplastic disease, suggesting good and complete response to therapy. Mild, linear and likely physiologic activity is seen in the descending colon and focal stasis is seen in the right distal ureter.