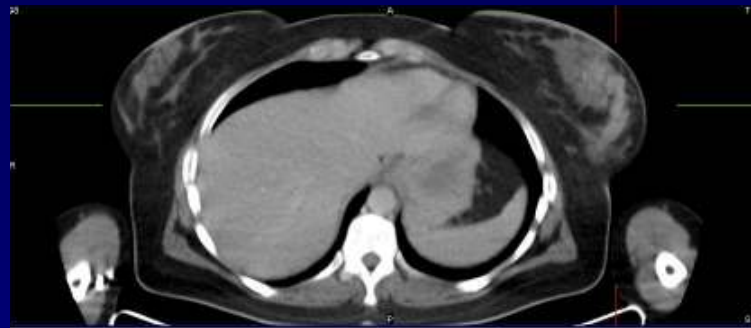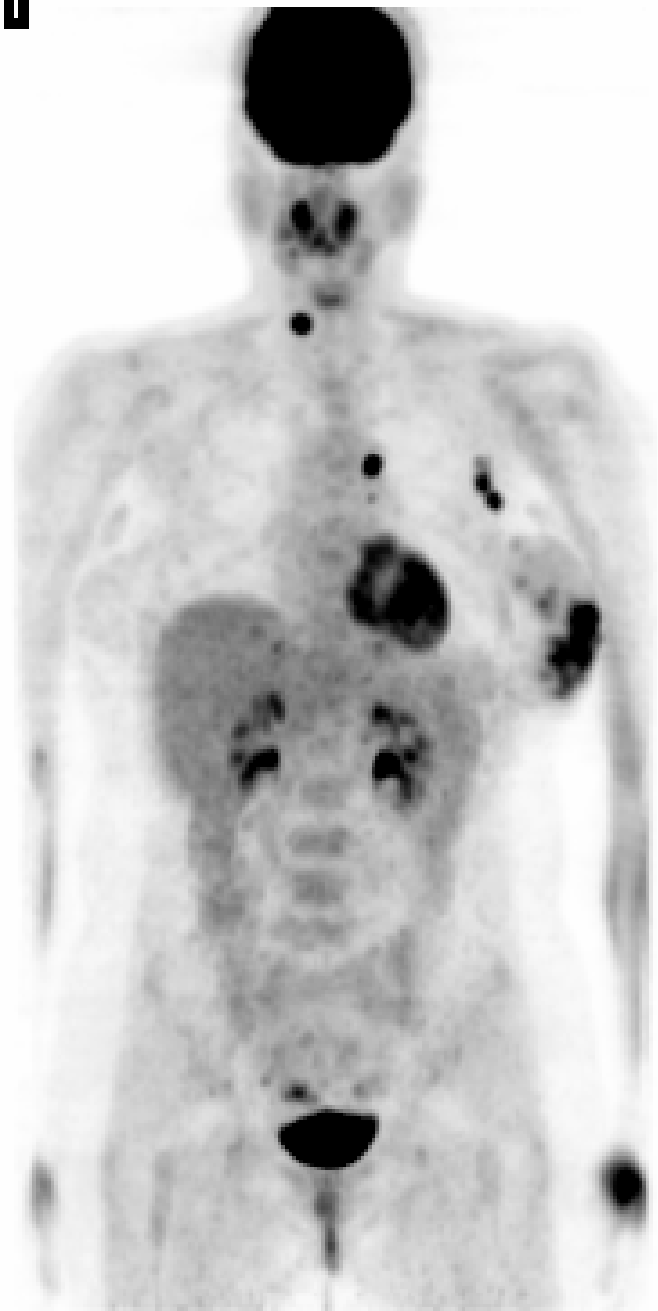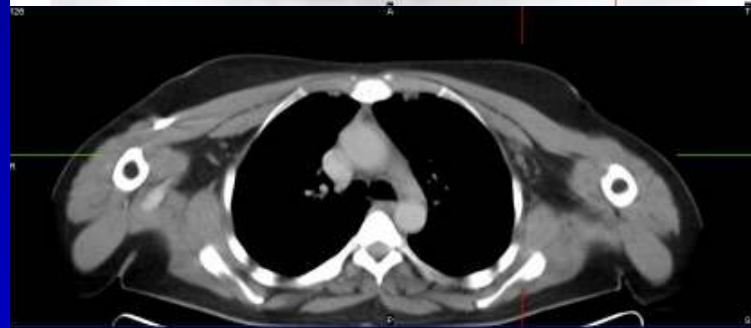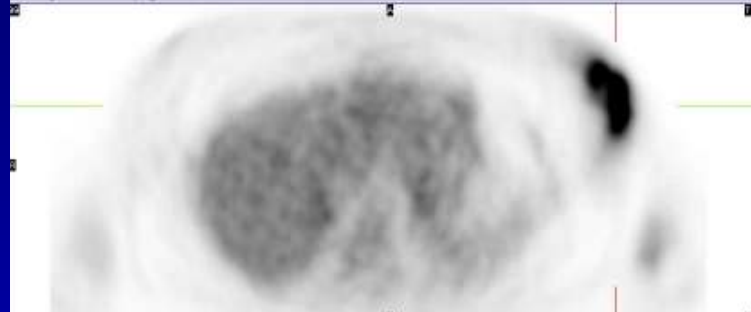


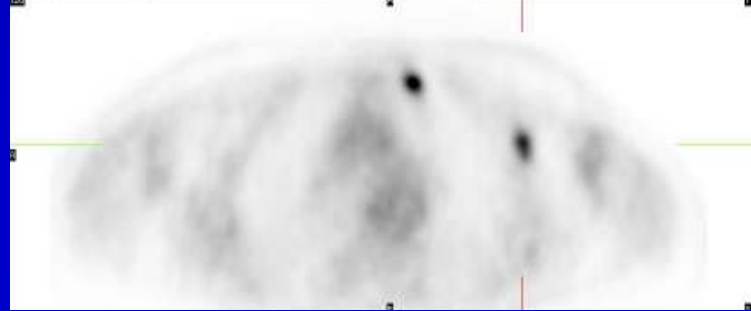
1



HJ[B-152,T232]
[ET]WB [Transformed Object], 3492066



HJ[B-152,T232]
[ET]WB [Transformed Object], 3492066



Case 105

The images show a large hypermetabolic mass in the left breast, likely to be consistent with primary breast cancer. Hypermetabolism in the left axillary and internal mammary adenopathy is likely to be consistent with nodal metastasis. Incidental hypermetabolism in the left thyroid nodule is suspicious for a second primary and should be evaluated further. Focal hypermetabolism in the uterus is a benign finding or a normal variant.

