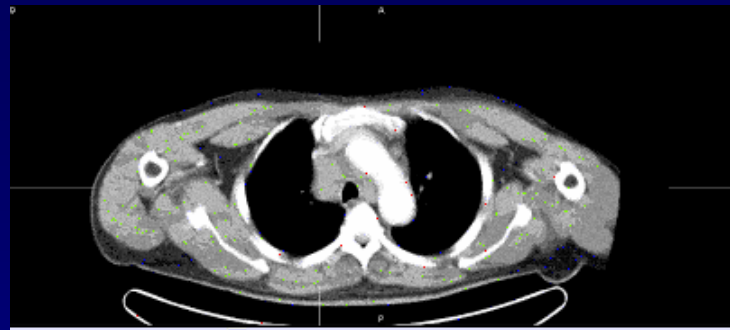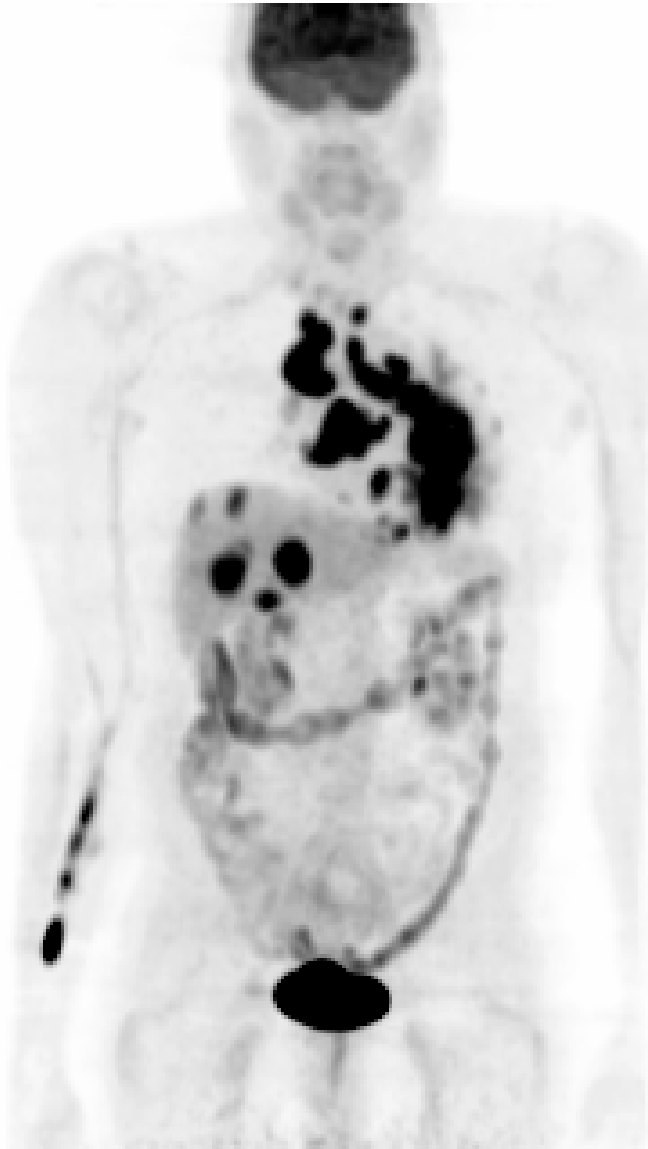
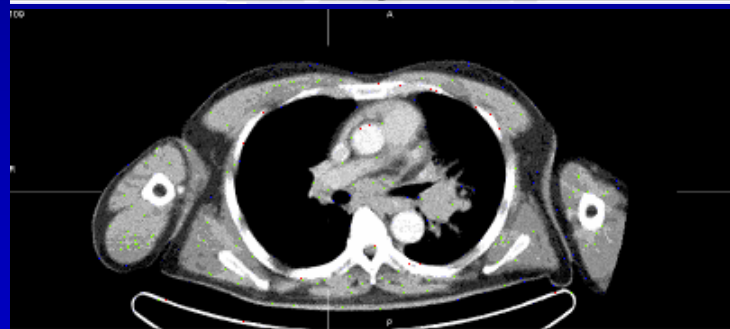
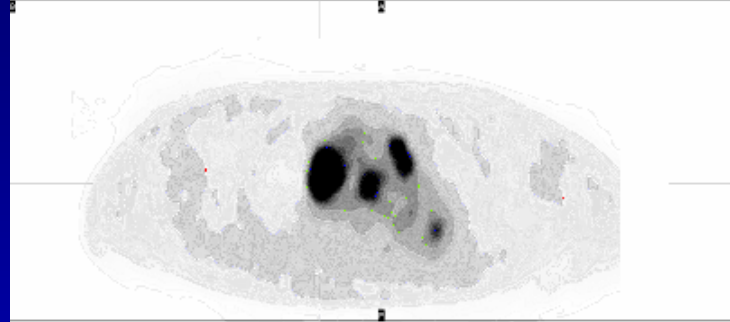


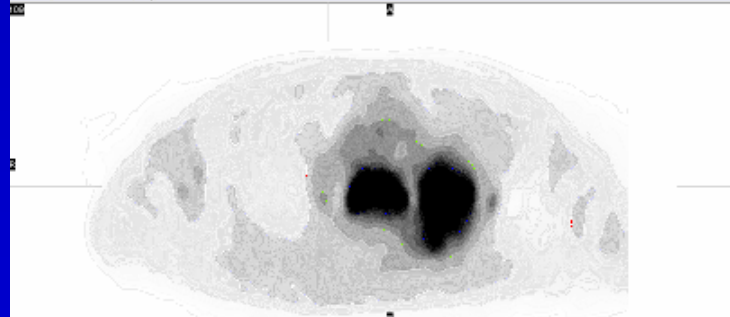
1



400-152.T.165
T.WB [Transformed Object], 20272006



400-152.T.165
PET.WB [Transformed Object], 20272006



Case 106

The images show a large hypermetabolic mass in the left hilar region, likely to be consistent with primary lung cancer. Hypermetabolism in the mediastinal nodes is likely to be consistent with nodal metastasis. Hypermetabolism in the multiple low density liver lesions is likely to be consistent with liver metastasis. Injection artifact is seen in the right forearm.

