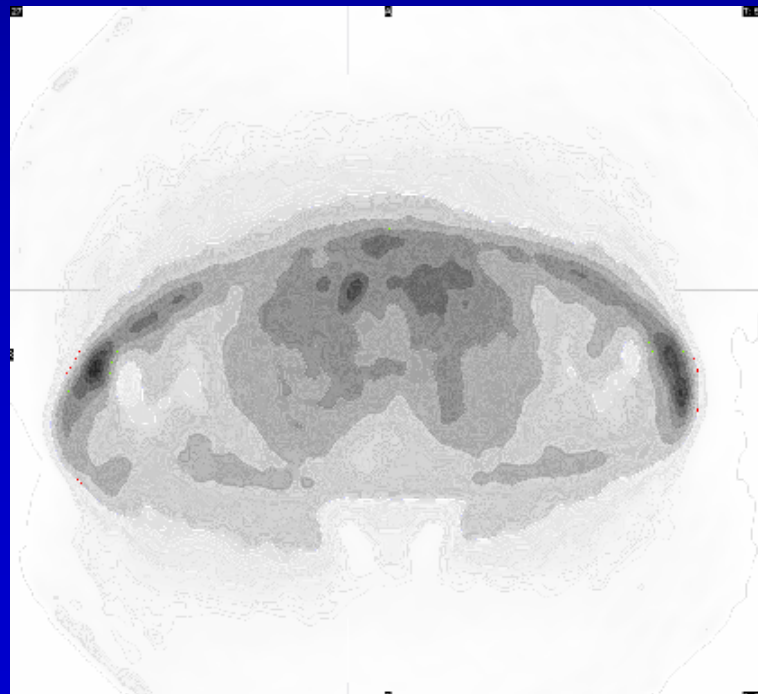
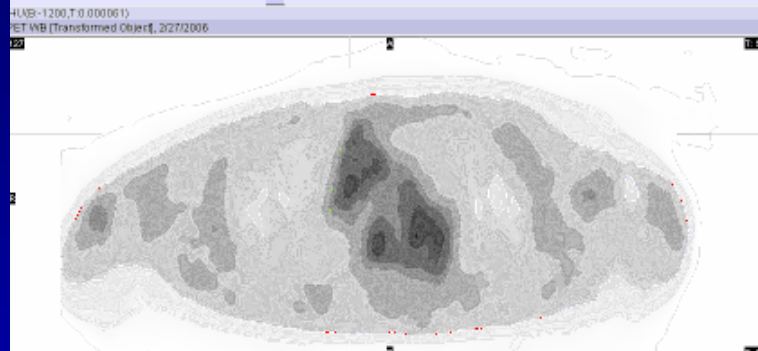
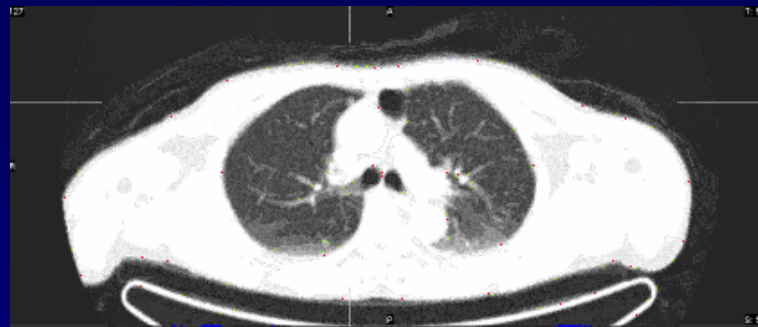
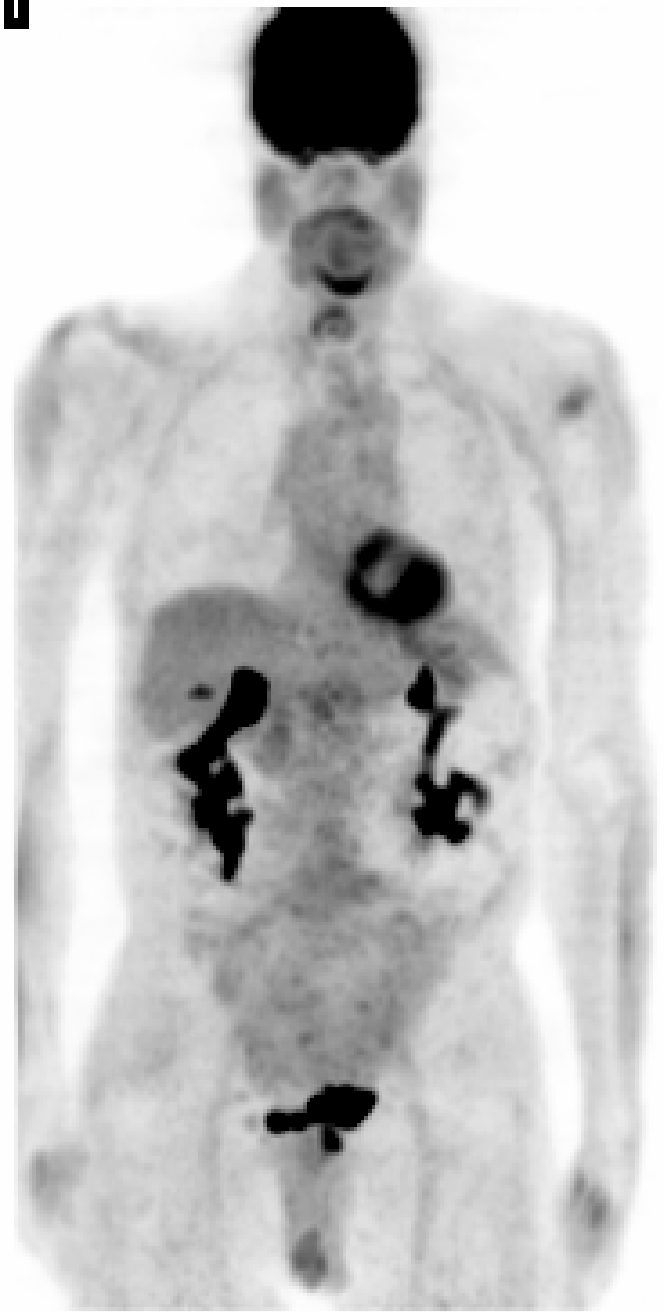
1



(LVB-1200.T.0.000061)
PET WB [Transformed Object, 2/27/2006]

Case 107

H/o rectal cancer and polycystic kidneys, presenting with a new lung nodule. The images show focal hypermetabolism in a presacral lymph node, likely to be consistent with neoplastic involvement. Mild focal hypermetabolism seen in the anterior, right lung nodule, best appreciated on the non attenuation corrected images is very suspicious for neoplastic involvement. Kidneys are enlarged and polycystic, the cysts being seen as photopenic defects on the PET images.

