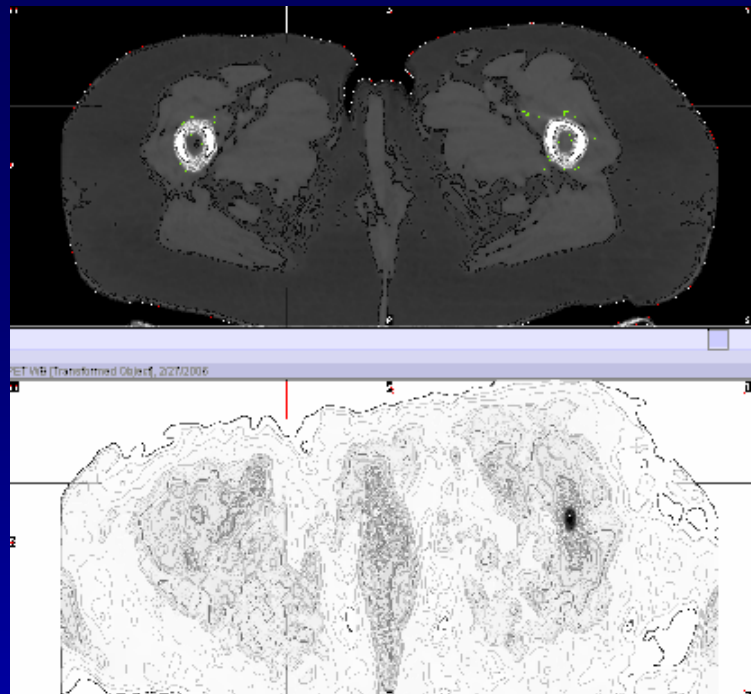
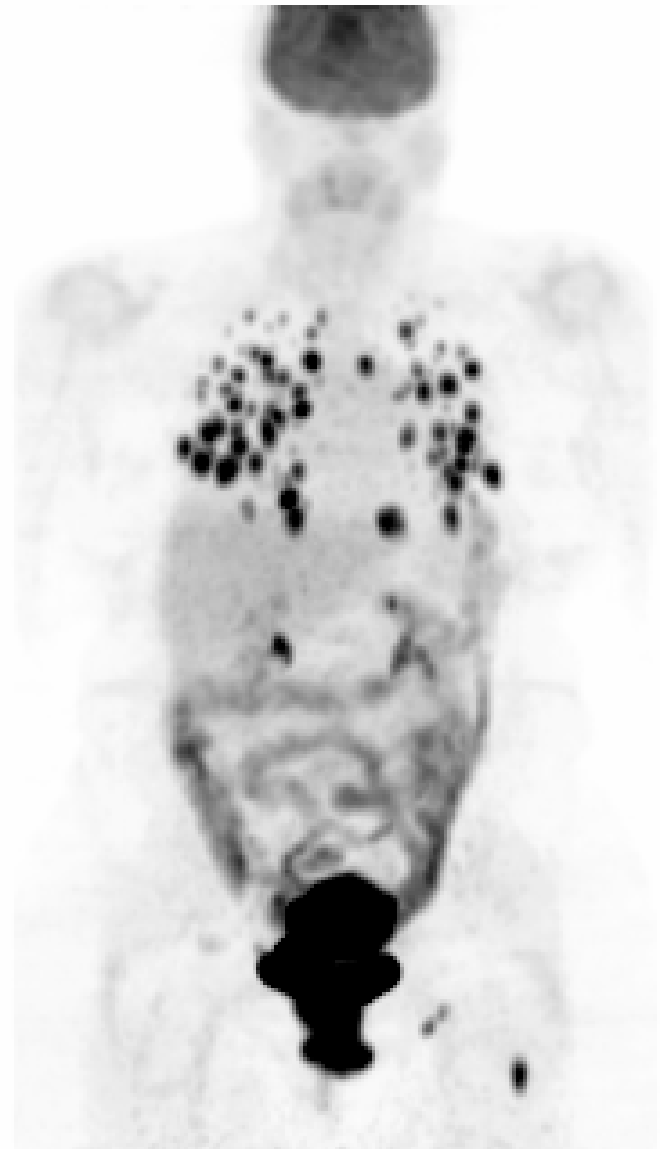


1



Case 108

Patient was newly diagnosed with endometrial cancer. The images show multiple hypermetabolic lung nodules, consistent with diffuse lung metastasis. Focal hypermetabolism is seen in the uterus, the primary and metastatic left inguinal nodes. Focal hypermetabolism seen in the left proximal femoral shaft, with minimal asymmetric soft tissue attenuation is most likely consistent with bone metastasis.