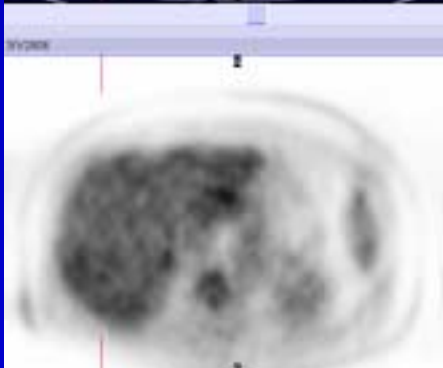
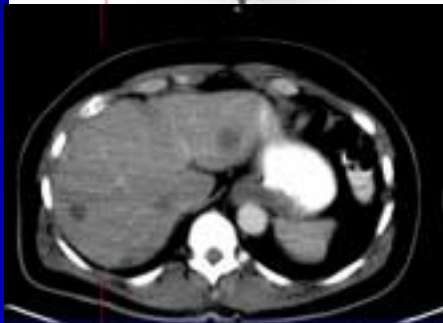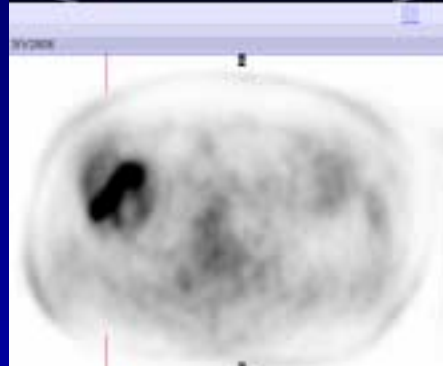
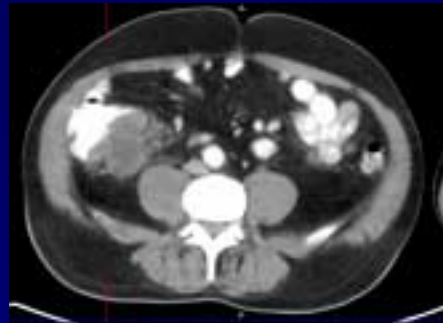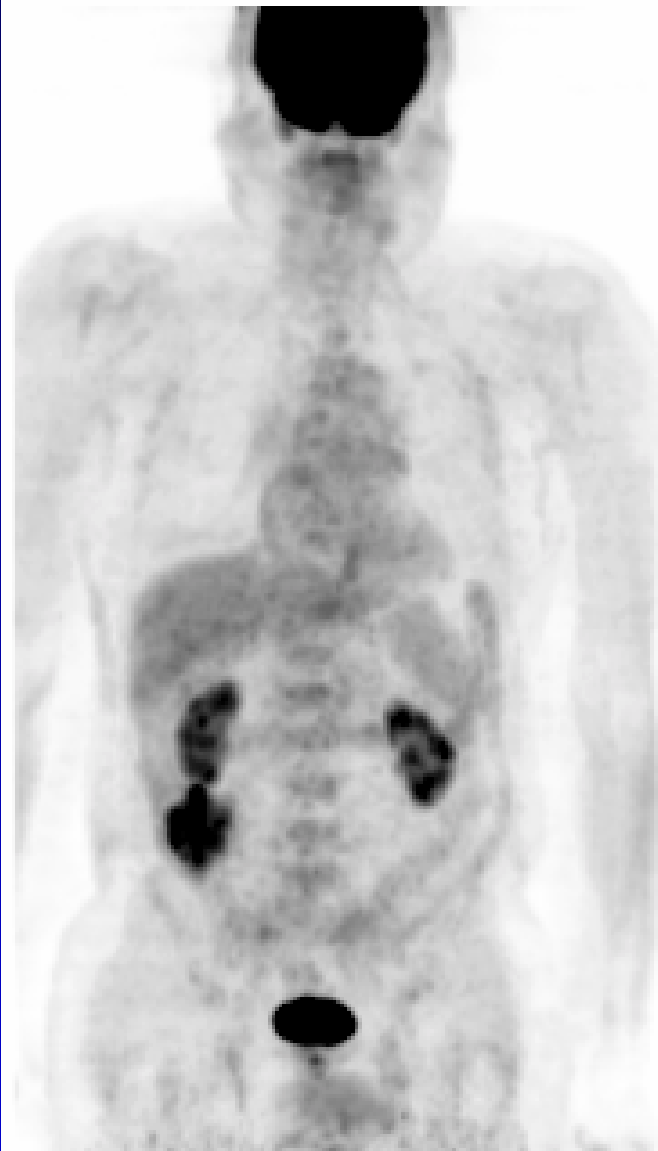


1



Case 110

A large hypermetabolic mass in the colon is likely to be consistent with primary colon cancer. Not appreciated on the rotating image are moderately hypermetabolic, multiple, hypodense lesions in the liver, likely to be consistent with liver metastasis.