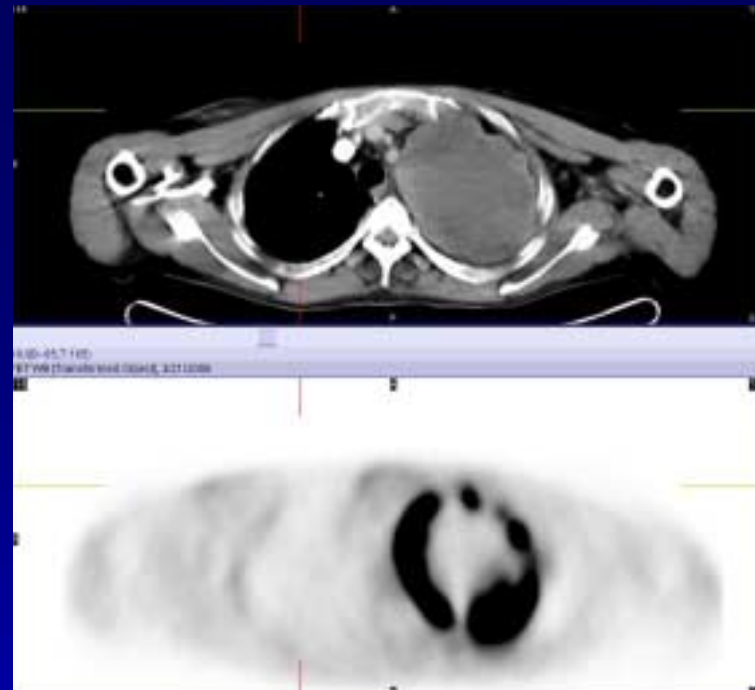
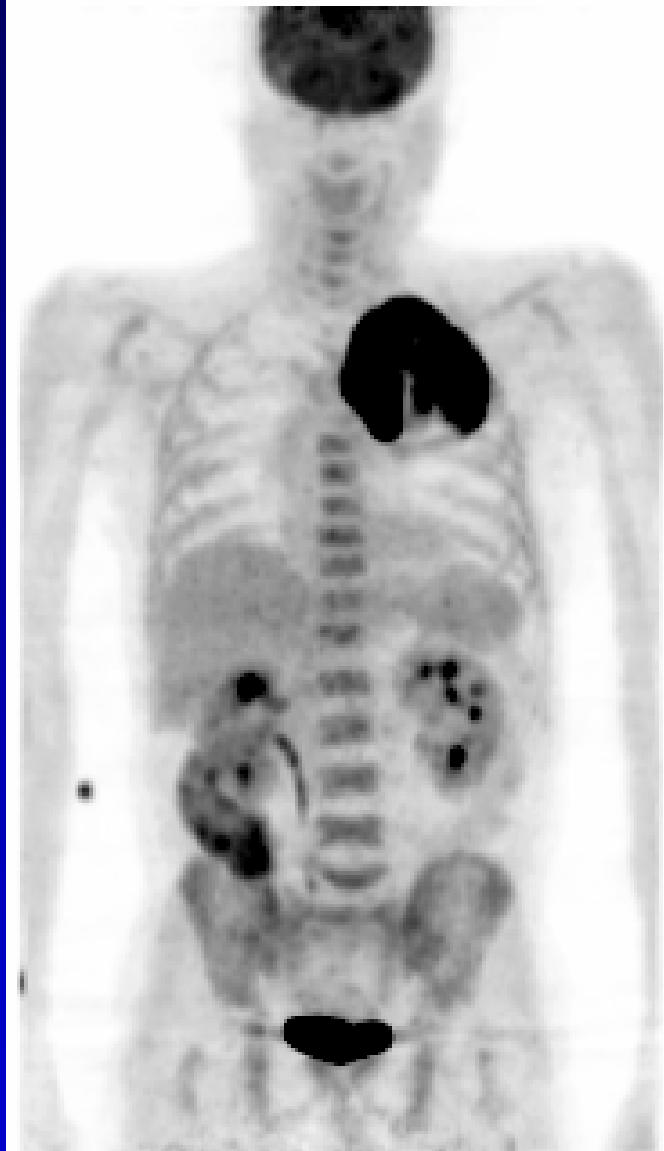

1



Case 113: Lung Cancer

H/o lung mass. Images show a large peripherally hypermetabolic mass in the left upper lobe, consistent with primary lung cancer and central necrosis. This pattern is more likely to be consistent with squamous cell cancer, rather than any other histologic subtype. There is no definite evidence of metastatic disease. Diffuse moderate FDG activity in the bone marrow is likely from bone marrow expansion from a benign cause such as anemia, rather than from neoplastic involvement. Focal hypermetabolism in the ascending colon should be evaluated further by colonoscopy. Injection artifact is seen in the right elbow.