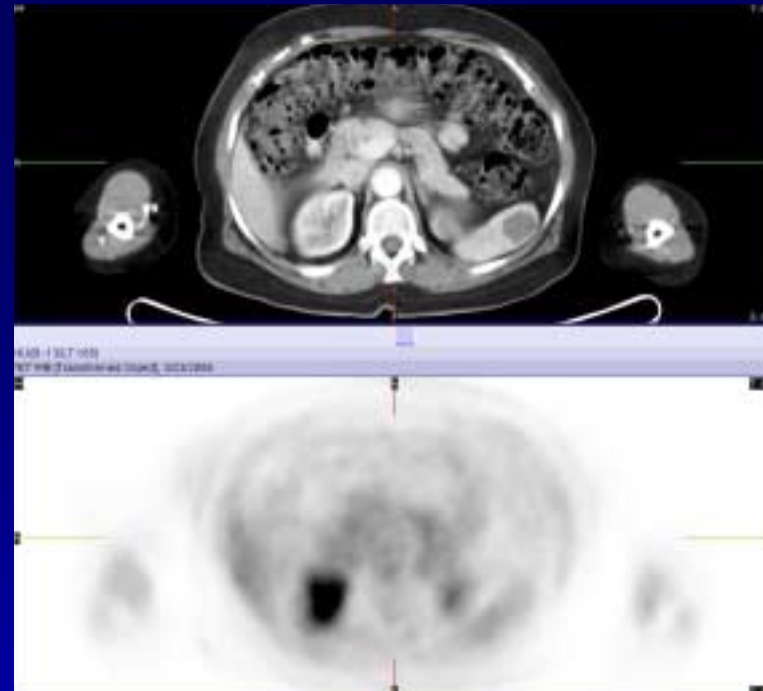
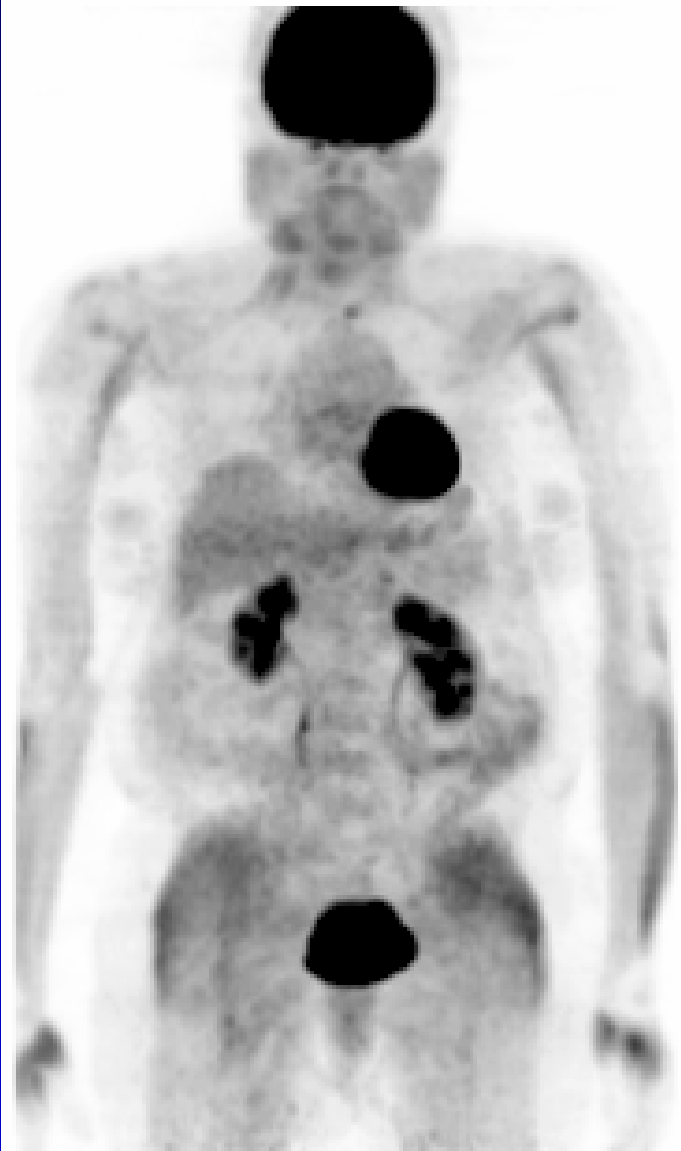


1



Case 114

H/o hypodense splenic mass, suspicious for neoplastic involvement. No focal abnormal hypermetabolism is seen in this lesion on the PET images. No other evidence of active neoplastic disease is seen. The rotating images show upper and lower extremity skeletal muscle uptake. Variable uptake can be seen in skeletal muscles depending on physical activity. Muscular uptake is usually mild to moderate in intensity, linear and symmetric. Administration of insulin or glucose or a recent meal can cause increased uptake in skeletal muscles, myocardium and fatty tissue.