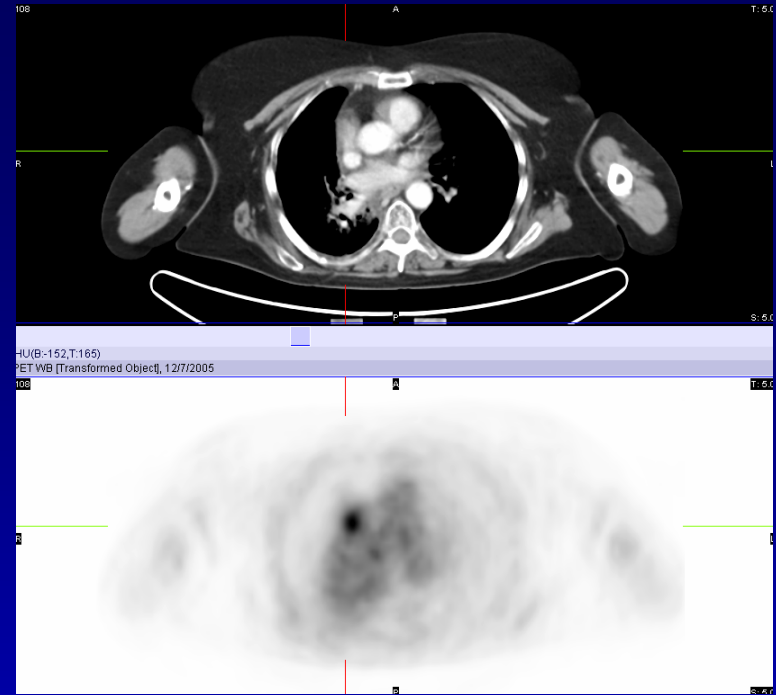
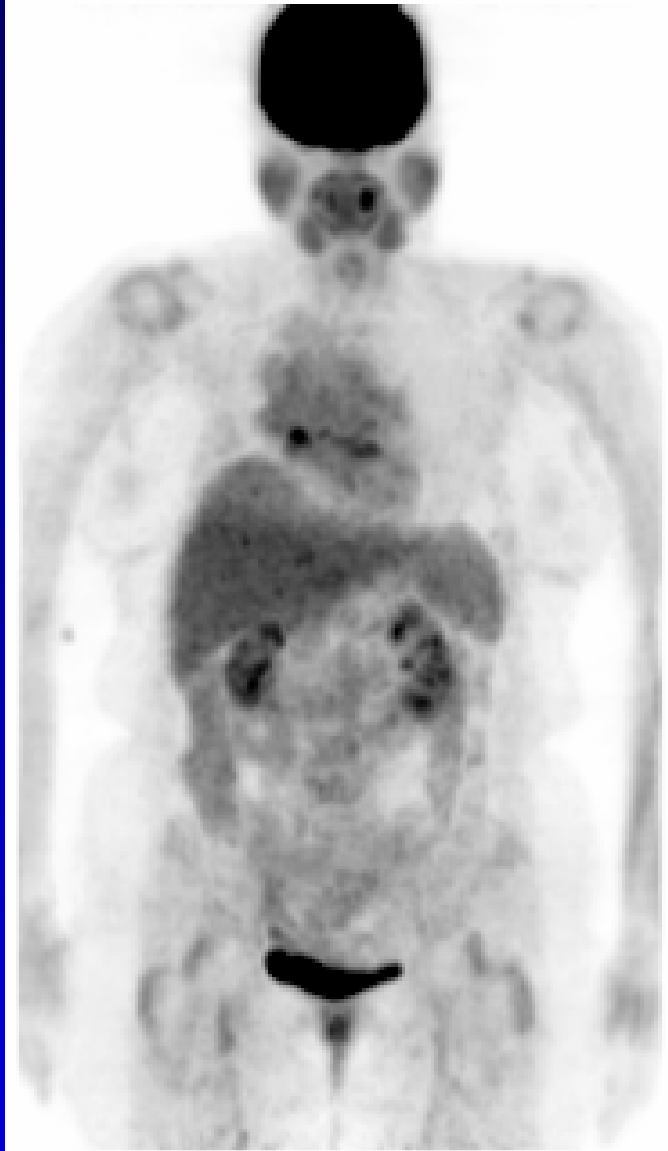


1



### Case 116

Focal FDG activity seen in the right atrium is likely physiologic uptake. Without CT correlation, this finding can be confused with metastatic adenopathy in the right hilum. Asymmetric activity is seen in the tonsils, also a normal variant. Mild, inflammatory/degenerative FDG activity is seen in the shoulders and hips.