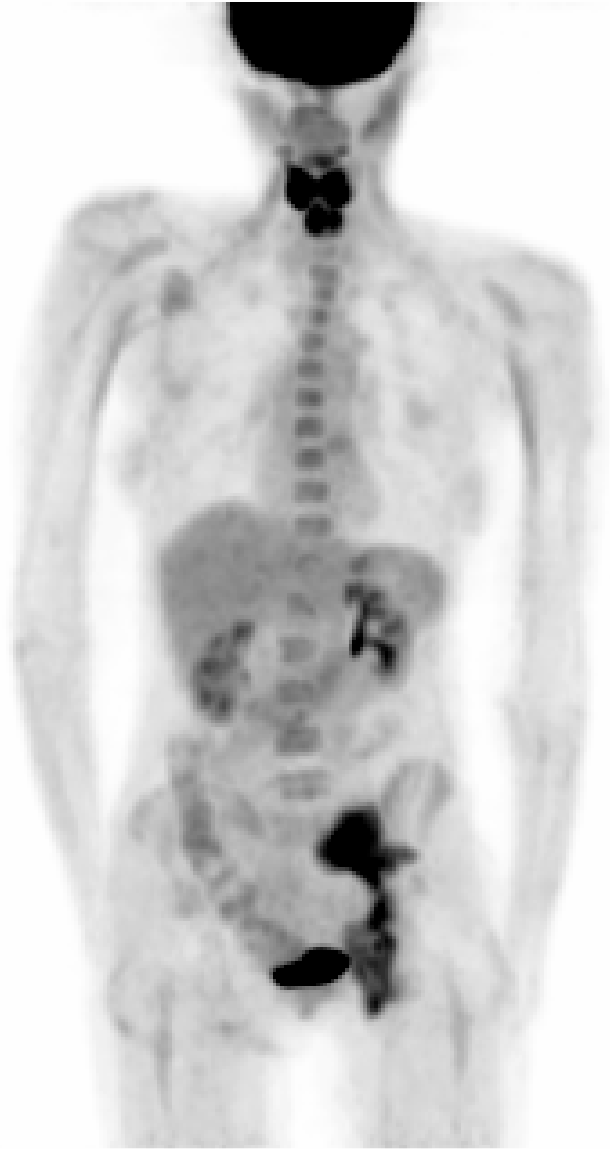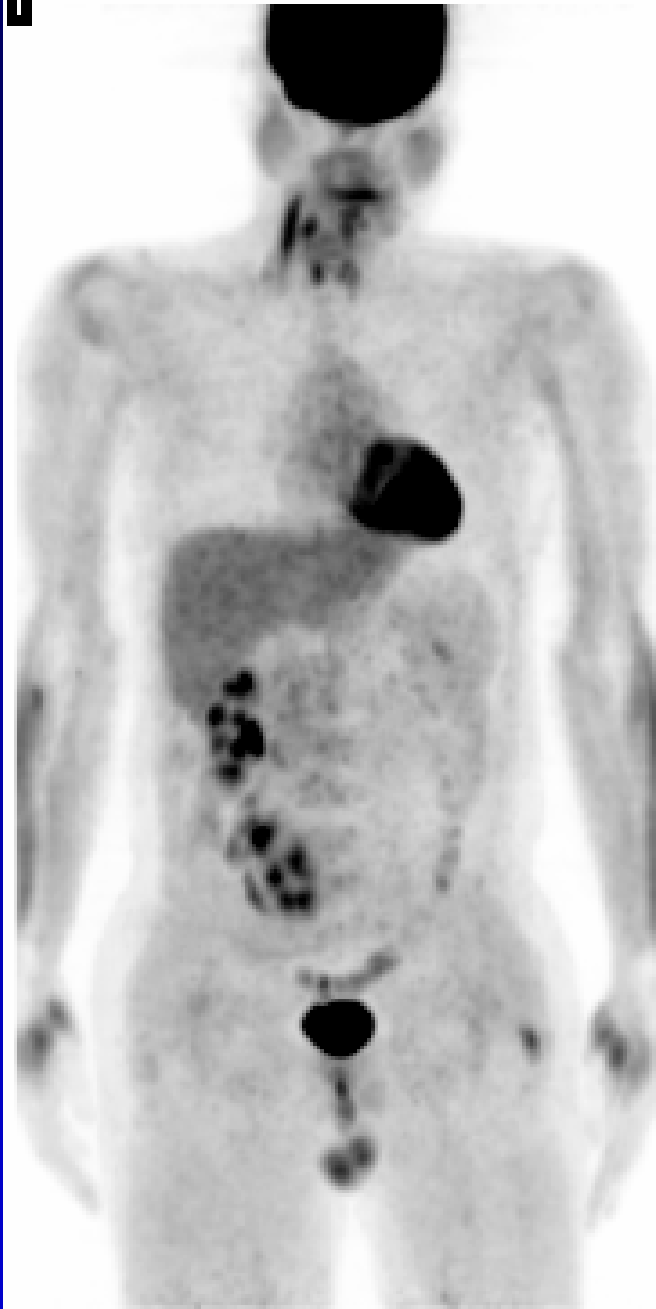


**1****1**

## Case 119

The image on the left shows intense, symmetric, and likely physiologic activity in the muscles of the tongue. There is also intense and likely inflammatory uptake in the perianal fistula. Bone marrow activity is likely from a benign cause of marrow expansion.

The image on the right shows physiologic activity in the neck muscles, testicles, and an ectopic left kidney, located in the right pelvic fossa.

There was no definite anatomic or functional imaging evidence of neoplastic disease.