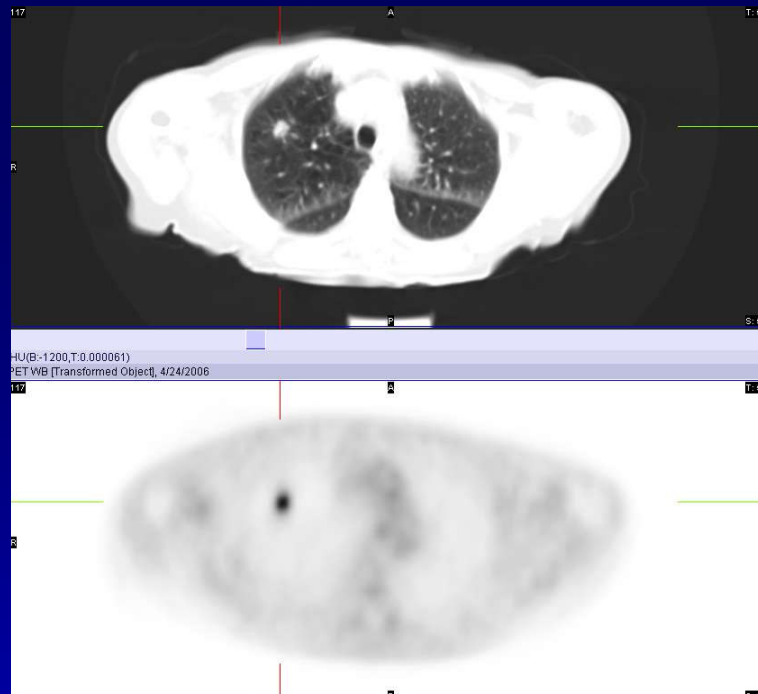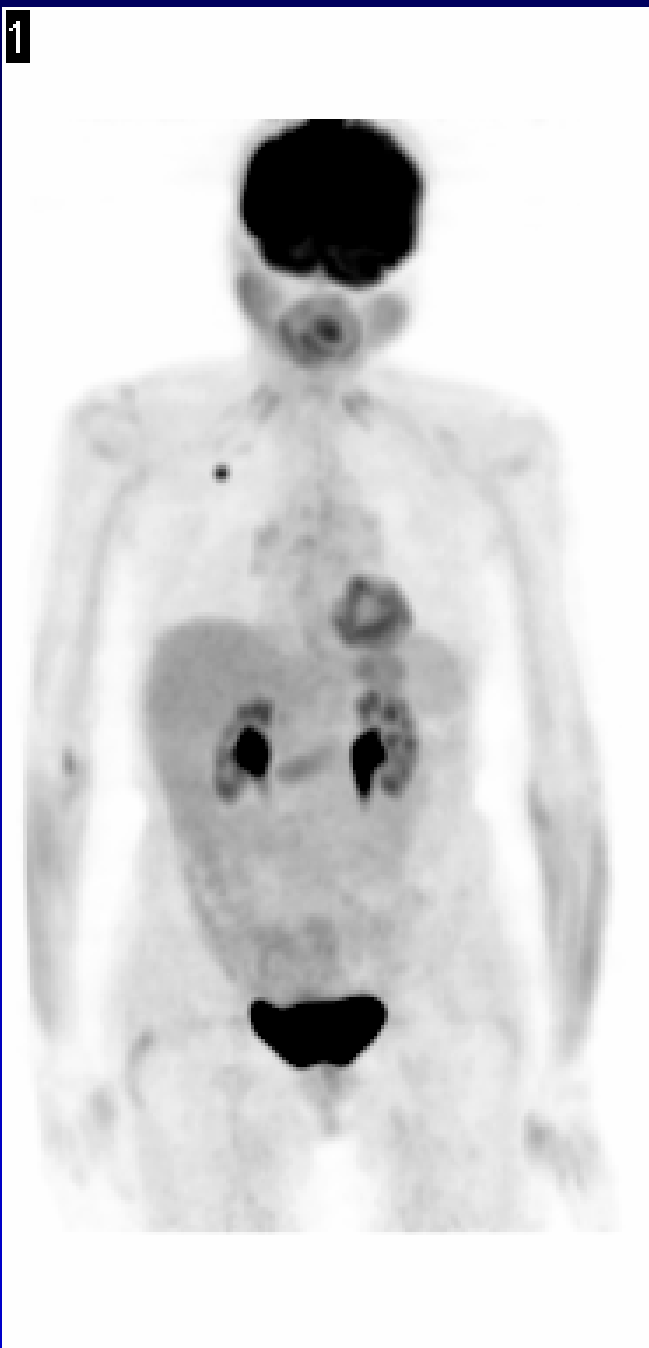


1



Case 120

H/o a 1 cm spiculated nodule in the right upper lobe seen on a recent chest X ray, in a chronic smoker. The PET images show focal hypermetabolism in the right upper lobe nodule, with SUV measuring 3.5, consistent with neoplastic involvement. No definite evidence of metastatic disease is seen.