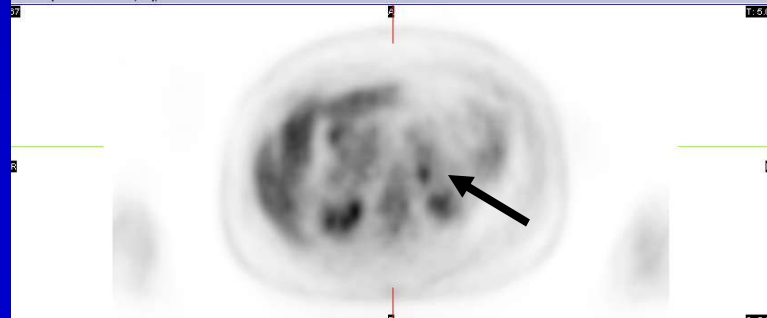
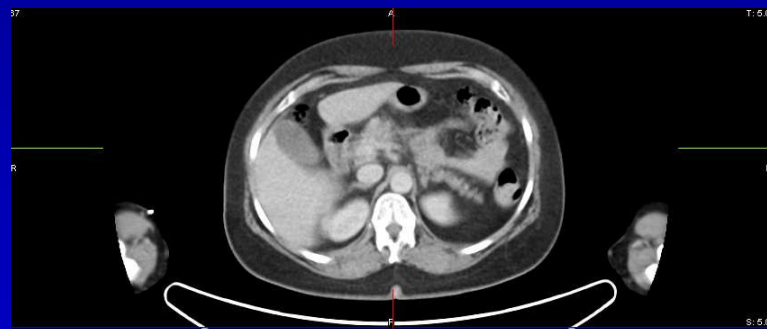
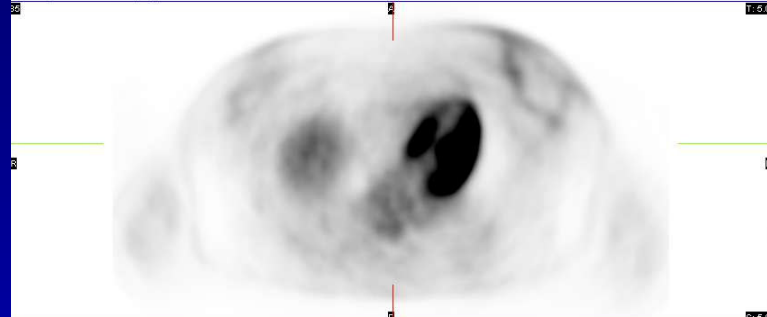
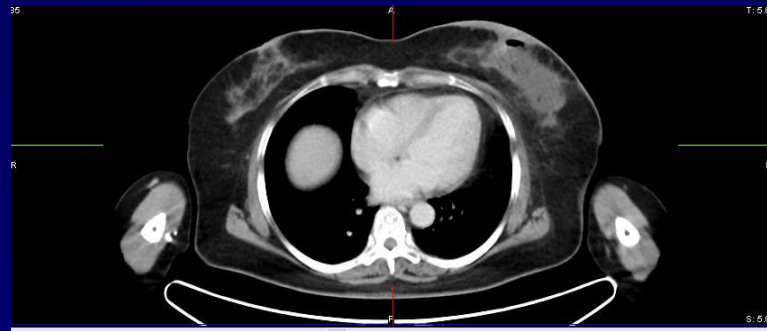
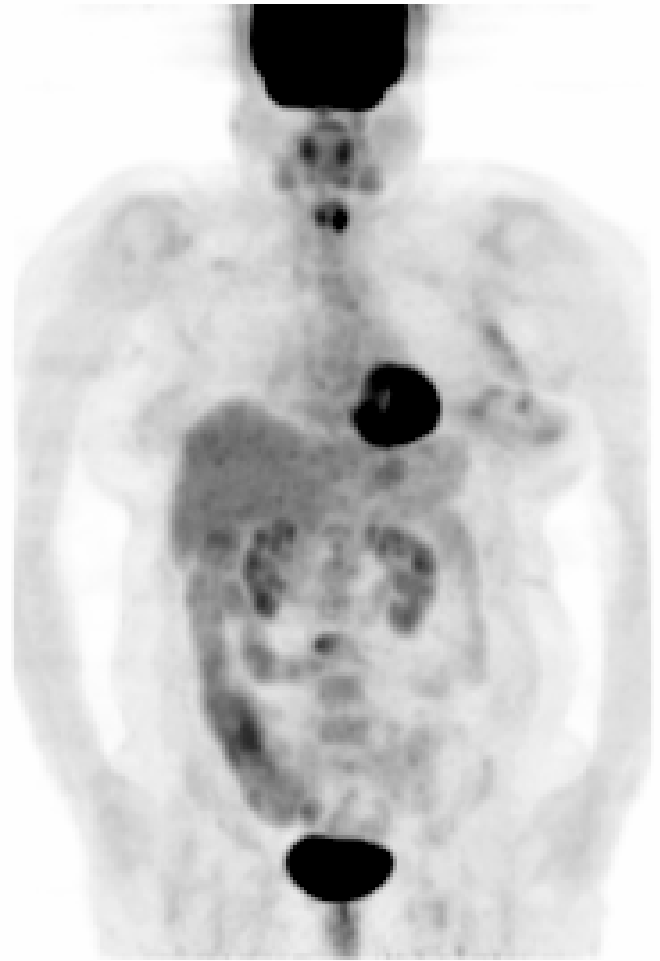
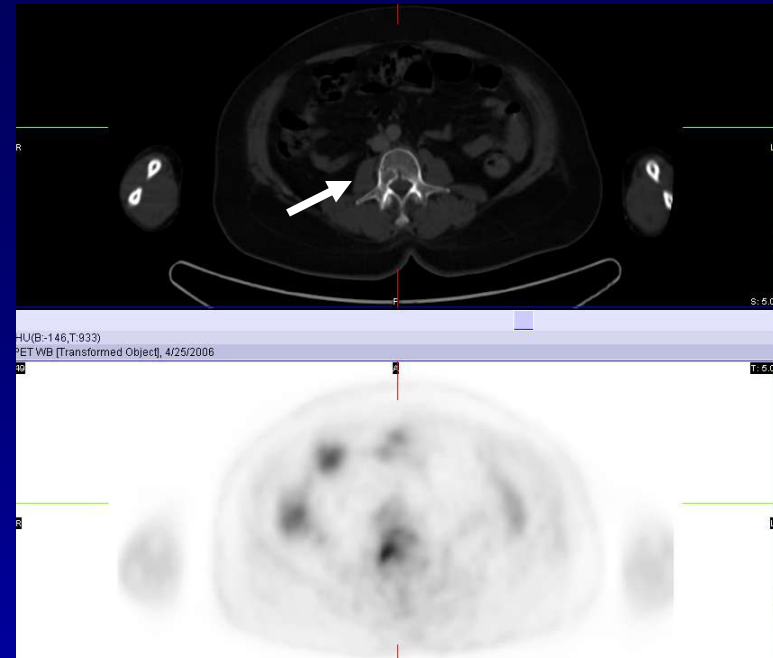
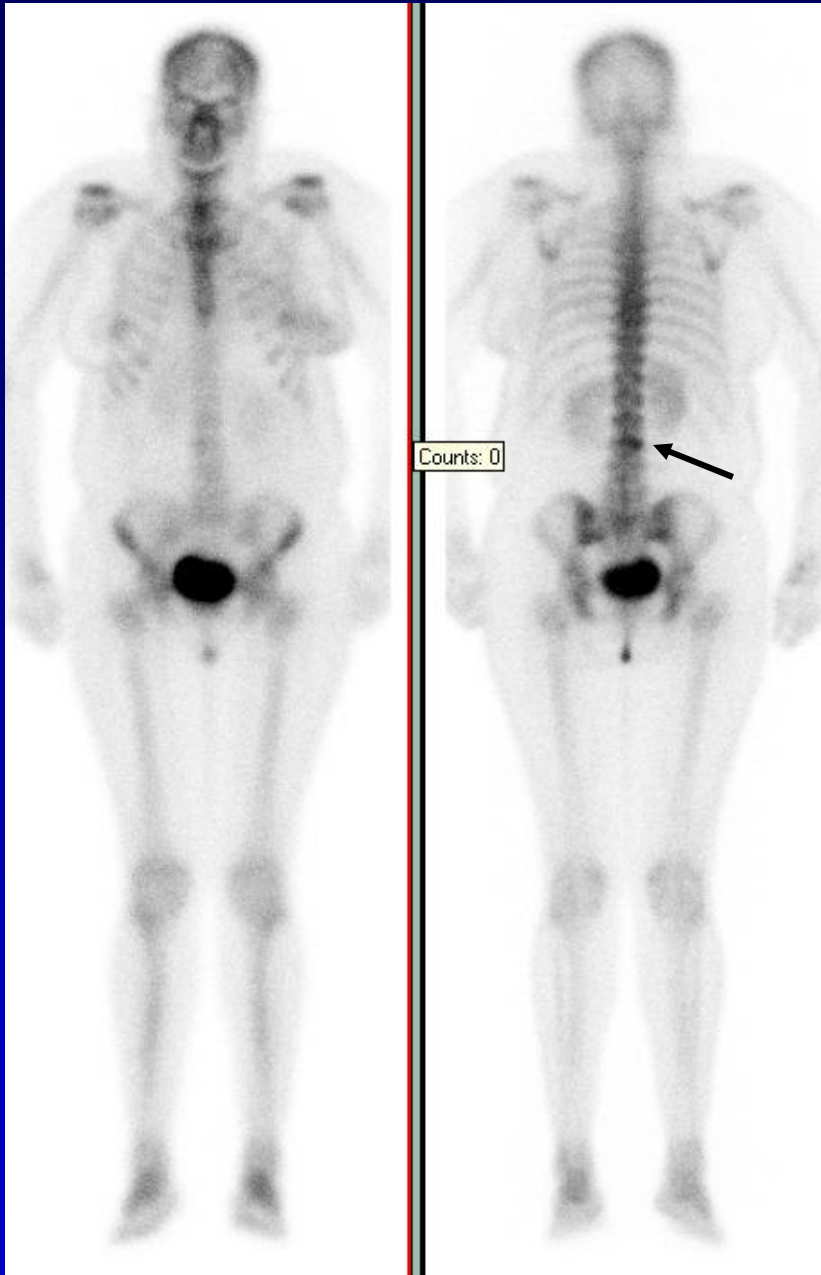


1





Case 121

After a recent left breast lumpectomy and axillary dissection, following lymphoscintigraphy procedure, patient had a whole body PET-CT which shows postoperative changes and inflammatory FDG activity in the left breast and axilla. Focal hypermetabolism (with activity more intense than the liver) in an anatomically normal looking adrenal is suspicious for adrenal metastasis and focal hypermetabolism seen in a small lytic lesion in the left side of the body of L3 vertebra is suspicious for bone metastasis. This focus is seen as a very subtle finding on the bone scan.