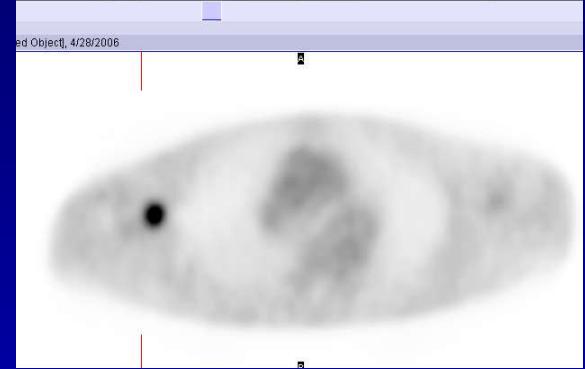
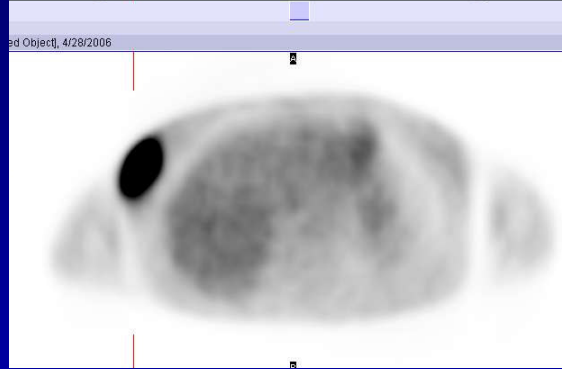
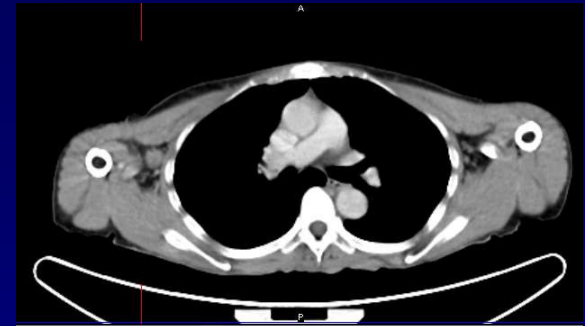
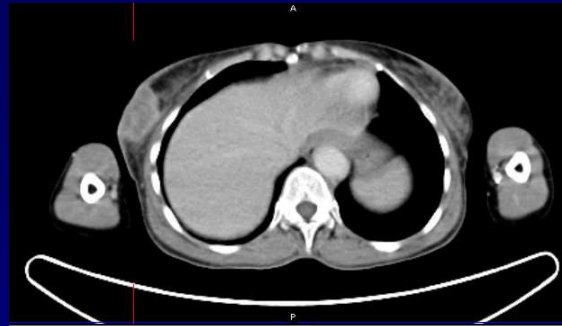
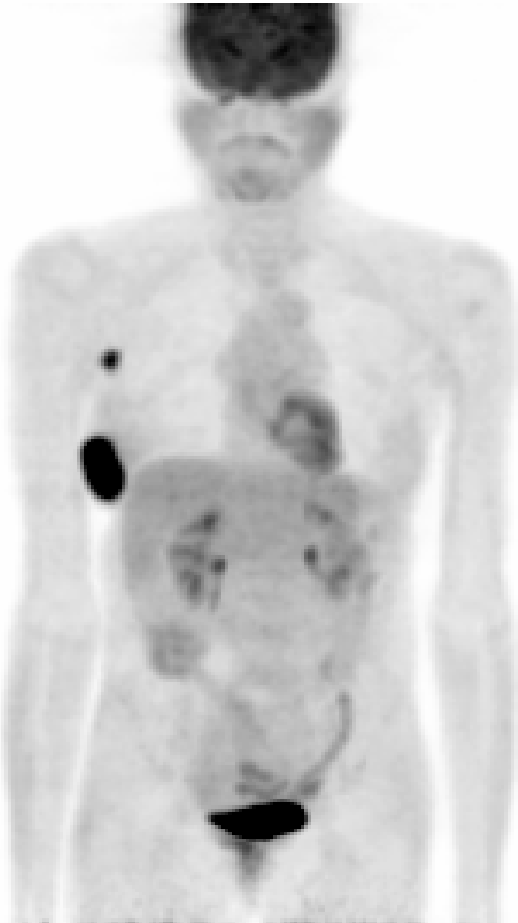


1



### Case 123

Hypermetabolism in the right breast mass and the axillary node are consistent with neoplastic involvement. "PET with FDG is currently most useful as a staging tool in breast cancer, especially in patients with recurrent or metastatic disease. It can also be used to measure response to therapy, possibly earlier than conventional methods.