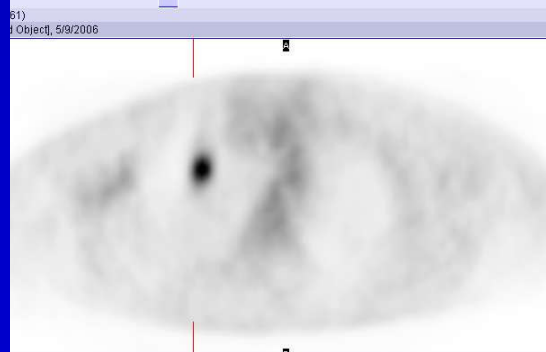
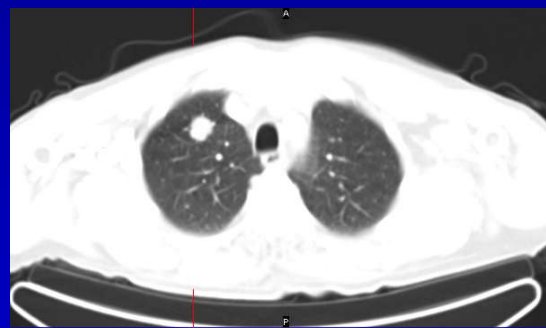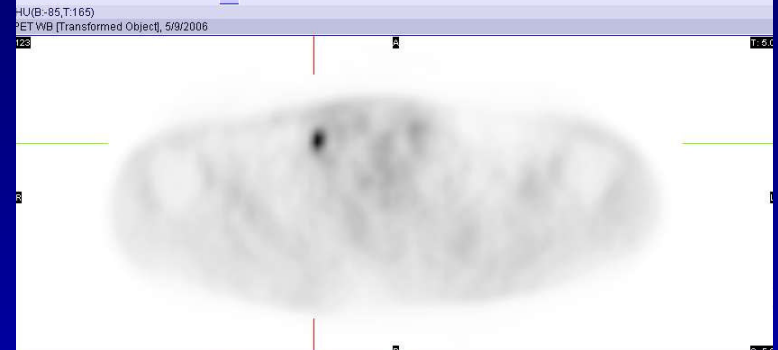
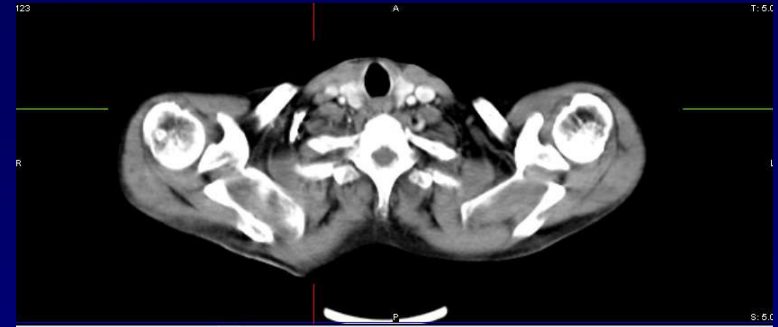
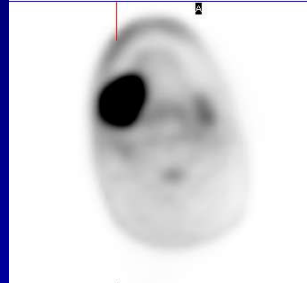
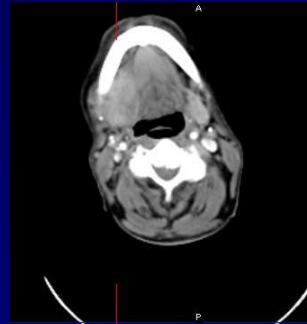
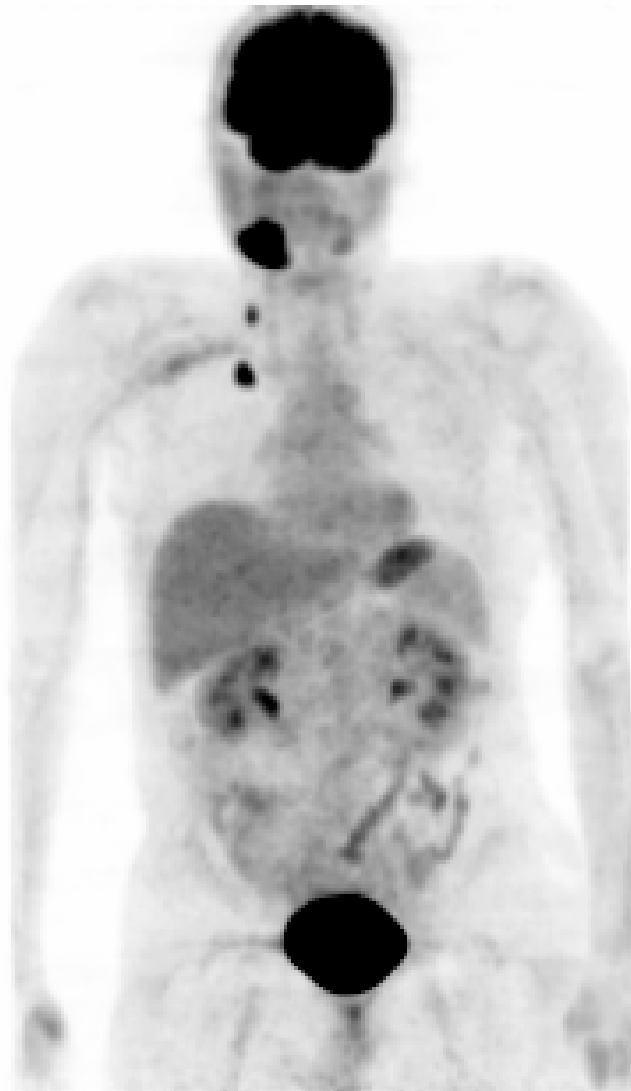


1



## Case 124

Hypermetabolic: right submandibular mass, right level IV neck node and the right apical lung nodule, all consistent with neoplastic involvement. The lung nodule could rarely be a second primary also.