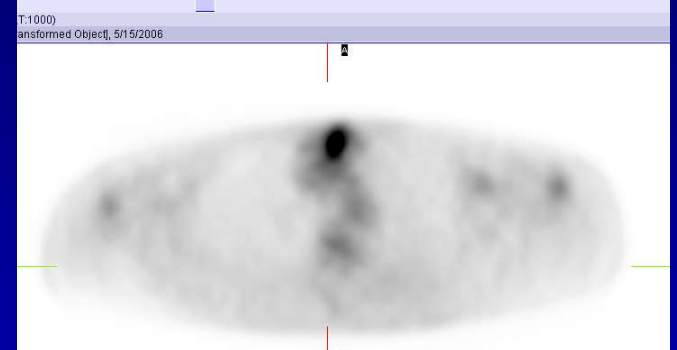
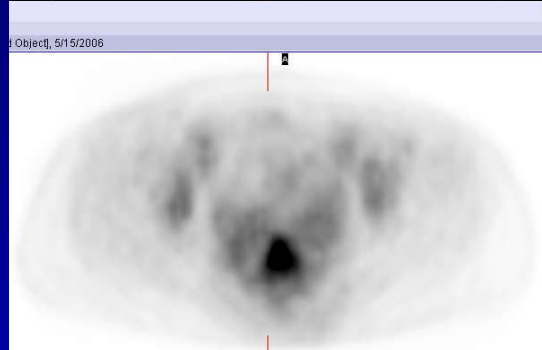
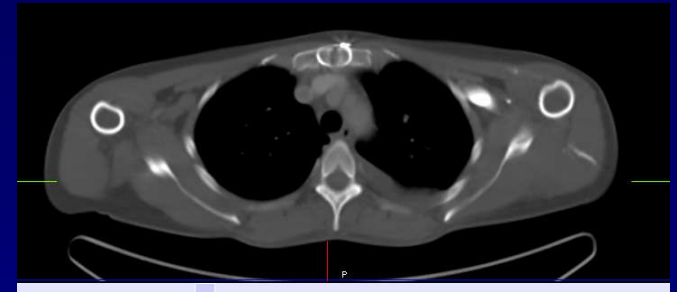
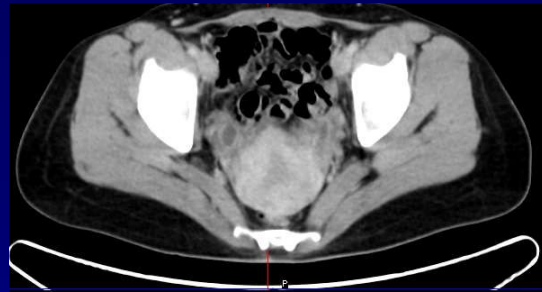
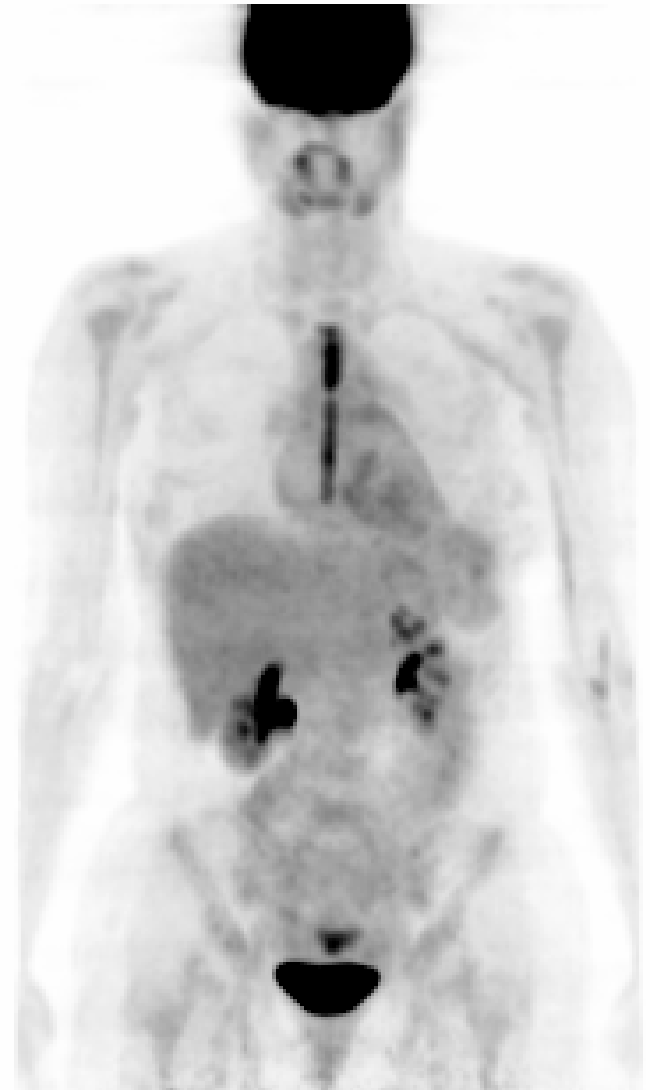1



Case 125

H/o breast cancer. The projection image does not show any definite evidence of recurrent or metastatic disease. Linear intense FDG activity in the sternum is inflammatory, post surgical in origin. Increased activity is also seen within the menstruating uterus.